

# Submacular hemorrhage secondary to congenital toxoplasmosis

Hemorragia submacular secundária à toxoplasmose congênita

Ana Luiza Fontes de Azevedo Costa<sup>1</sup>, Thiago Gonçalves dos Santos Martins<sup>2</sup>,  
Francisco Javier Solano Moncada<sup>3</sup>, Mário Martins dos Santos Motta<sup>1</sup>

## ABSTRACT

We report the case of a patient with congenital toxoplasmosis and submacular hemorrhage caused by a neovascular membrane who underwent an intravitreal injection of C3F8 and bevacizumab, and had a good visual recovery.

**Keywords:** Toxoplasmosis, congenital/etiology; Retinal hemorrhage/etiology; Intravitreal injections/adverse effects; Retinal neovascularization/complications; Angiogenesis inhibitors; Tomography, optical coherence; Case reports

## RESUMO

Relatamos o caso de uma paciente com toxoplasmose congênita e hemorragia submacular por uma membrana neovascular submetida à injeção intravítrea de C3F8 e bevacizumabe, com boa recuperação visual.

**Descritores:** Toxoplasmose congênita/etiologia; Hemorragia retiniana/etiologia; Injeções intravítreas/efeitos adversos; Neovascularização retiniana/complicações; Inibidores da angiogênese; Tomografia de coerência óptica; Relatos de casos

## INTRODUCTION

The retinochoroiditis is the most common manifestation of congenital toxoplasmosis that is bilateral in 50 to 80% of cases. This inflammation could also compromise the retinal vascular system and the formation of subretinal neovascular membrane, which could be seen in the edge of the lesion or distant from the edge with nourishing arteries arising from the scar.<sup>(1)</sup>

We report a case of patient with congenital toxoplasmosis caused by subretinal neovascular membrane with a submacular hemorrhage that, although infrequent, could promote important consequences because of the visual acuity reduction. Despite this fact, it could be treated with possibility of recovering.

## CASE REPORT

LSE, an 18-year-old student woman was admitted to the *Hospital das Clínicas da Faculdade de Medicina da Universidade de São Paulo* on February 2010, with low visual acuity for 1 week. The patient was diagnosed with ocular congenital toxoplasmosis by the age 15 years old.

An ophthalmologic exam performed at admission showed corrected visual acuity with counting finger from 1m in the right eye and hand motion in the left eye. The visual acuity in the left eye of the patient was 20/20 without correction, which happened before she develops the reported episode according to information collected from the medical record. In order to register and support the diagnosis a retinography and an angiofluoresceinography were conducted (Figure 1). On February 18, 2010 the patient, in face-down position, received an intravitreal injection of 0.3mL of C3F8 in left eye.

One day after the procedure the patient was presenting vision of 20/50 and inferior displacement of submacular hemorrhage (Figure 2).

<sup>1</sup>Hospital Federal dos Servidores do Estado, Rio de Janeiro, RJ, Brazil.

<sup>2</sup>Universidade Federal de São Paulo, São Paulo, SP, Brazil.

<sup>3</sup>Universidade de São Paulo, São Paulo, SP, Brazil.

Corresponding author: Ana Luiza Fontes de Azevedo Costa – Rua Sacadura Cabral, 178 – Saúde – Zip code: 20221-161 – Rio de Janeiro, RJ, Brazil – Phone: (55 21) 3228-2209 – E-mail: luizafacosta@hotmail.com

Received on: Dec 17, 2012 – Accepted on: Dec 5, 2013

DOI: 10.1590/S1679-45082014RC2708

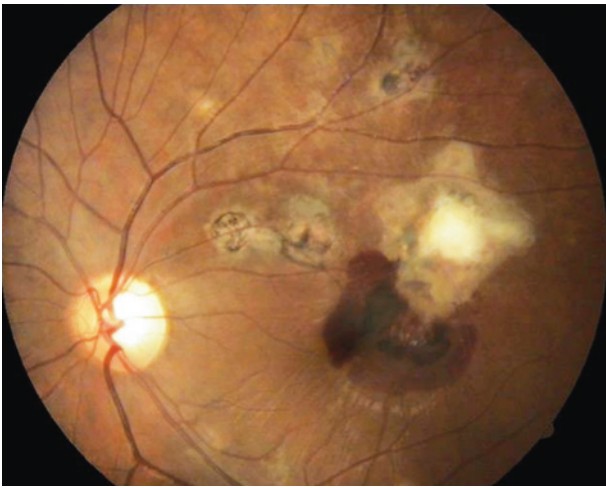


Figure 1. Scar area with submacular hemorrhage in the left eye

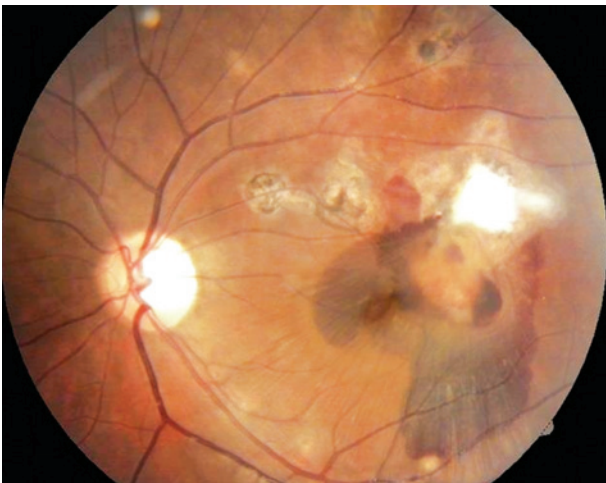


Figure 2. First day after intravitreal injection of C3F8

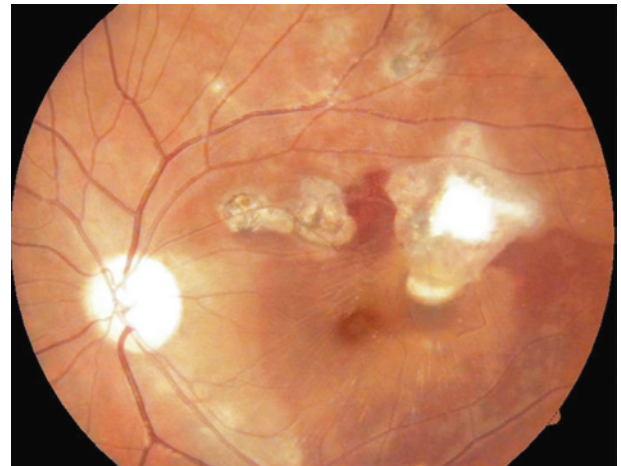


Figure 3. One week after intravitreal injection of C3F8

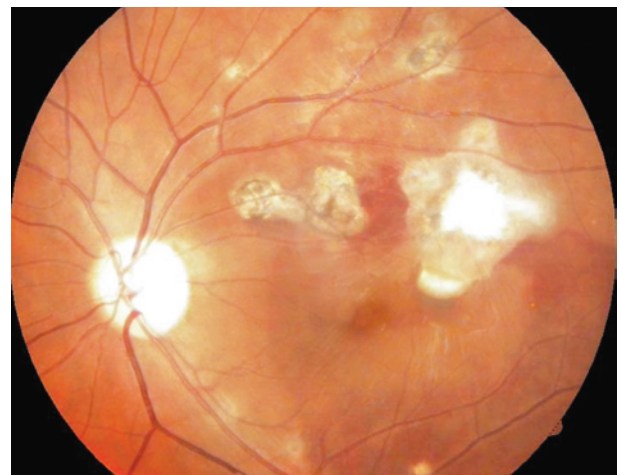


Figure 4. One week after intravitreal injection of bevacizumab

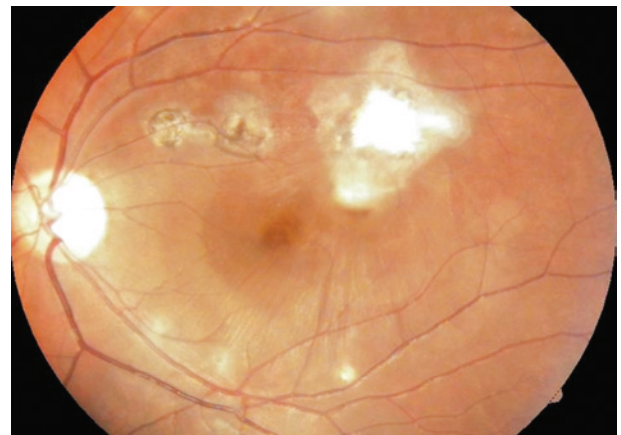


Figure 5. Six months after intravitreal injection of bevacizumab

On August 25, 2010 a reduction of visual acuity to 20/200 was seen. The funduscopy revealed partial absorption of hemorrhage but with macular edema (Figure 3). Based on this clinical feature, on March 1, 2010 an intravitreal bevacizumab injection was conducted.

A week after this procedure the patient showed visual acuity of 20/20 in the left eye. The retinography showed a higher reduction of submacular hemorrhage and hyperfluorescence due to impregnation of neovascular membrane without significant leakage. The optical coherence tomography found a neovascular membrane in front of pigment epithelium without significant intraretinal edema (Figure 4).

After 6 months of follow-up, the visual acuity of 20/20 in the left eye was maintained and no signs of membrane activity were found in funduscopy, fluorescein angiography and optical coherence tomography (Figure 5).

## DISCUSSION

Choroidal neovascular membrane is a rare complication of toxoplasmic chorioretinitis related to the production of vascular endothelial growing factor.<sup>(2)</sup>

Studies that analyzed the causes of submacular hemorrhage found that those secondary to age-related macular degeneration (ARMD) present a worse visual prognosis than those secondary to trauma, macroaneurysm or congenital toxoplasmosis.<sup>(3)</sup>

The treatment with low doses (18 to 50mg) of intravitreal tissue plasminogen activator and 0.3mL perfluoropropane followed by face-down position for 3 days, present good results in patients with submacular hemorrhage secondary to ARMD.<sup>(4)</sup>

There are studies showing that children with neovascular membrane had better visual recovery than adults.<sup>(5)</sup>

A study with intravitreal injection of C3F8 and bevacizumab, the same injection used in our case, reported good visual recovery, probably because it removed the blood in macular region, which decreases the toxicity to photoreceptors.<sup>(6)</sup> The blood in macular region that come in contact with photoreceptors leads to edema of these receptors after 1 hour of bleeding and causes the destruction of external nuclear layer in 2 weeks due to toxic effects of iron in the hemoglobin.<sup>(7)</sup> The objective of bevacizumab use is to reduce the vascular permeability that provokes an involution of subretinal neovascular membrane.<sup>(6)</sup>

Other method reported in the literature for treatment of submacular hemorrhage secondary to congenital toxoplasmosis, which presented good results, was the photodynamic therapy.<sup>(8)</sup>

## CONCLUSION

Although unusual, the submacular hemorrhage must be considered in patients with congenital toxoplasmosis

who already had scars and subretinal membrane with good visual acuity that evolved with sudden decrease of vision. The lack of studies comparing natural evolution of neovascular membrane secondary to toxoplasmosis scar in the eye enables to state that the best treatment for retinochoroiditis would be the one reported in this case especially for young patients with normal vision in only one eye.

## REFERENCES

1. Oréfice F, Santos VD, Oréfice JL. Toxoplasmose In: Oréfice F, Santos VD, Oréfice JL. Uveítes e oncologia ocular. 2a ed. Rio de Janeiro: Guanabara Koogan; 2011. p.131-56.
2. Benevento JD, Jager RD, Noble AG, Latkany P, Mieler WF, Sautter M, Meyers S, Mets M, Grassi MA, Rabiah P, Boyer K, Swisher C, McLeod R; Toxoplasmosis Study Group. Toxoplasmosis-associated neovascular lesions treated successfully with ranibizumab and antiparasitic therapy. *Arch Ophthalmol.* 2008;126(8):1152-6.
3. Berrocal MH, Lewis ML, Flynn HW Jr. Variations in the clinical course of submacular hemorrhage. *Am J Ophthalmol.* 1996;122(4):486-93.
4. Handwerker BA, Blodi BA, Chandra SR, Olsen TW, Stevens TS. Treatment of submacular hemorrhage with low-dose intravitreal tissue plasminogen activator injection and pneumatic displacement. *Arch Ophthalmol.* 2001;119(1):28-32.
5. Uemura A, Thomas MA. Visual outcome after surgical removal of choroidal neovascularization in pediatric patients. *Arch Ophthalmol.* 2000;118(10):1373-8.
6. Ferraz DA, Bressanim GL, Morita C, Takahashi WY. Injeção intravítrea de bevacizumab e gás C3F8 para tratamento da hemorragia submacular secundária de degeneração macular relacionada à idade: relato de casos. *Arq Bras Oftalmol.* 2010;73(1):77-80.
7. Glatt H, Machemer R. Experimental subretinal hemorrhage in rabbits. *Am J Ophthalmol.* 1982;94(6):762-73.
8. Oliveira LB, Reis PA. Photodynamic therapy-treated choroidal neovascular membrane secondary to toxoplasmic retinochoroiditis. *Graefes Arch Clin Exp Ophthalmol.* 2004;42(12):1028-30.